

in-stent stenosis following stent assisted coiling of a right middle cerebral artery aneurysm

PHYSICIAN'S CONCERNS?

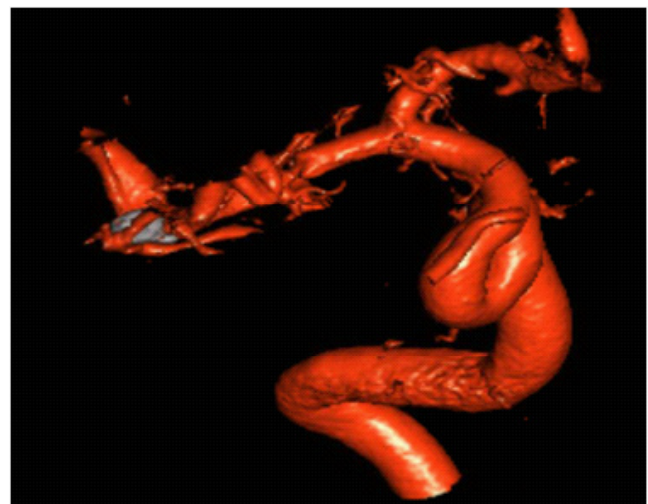
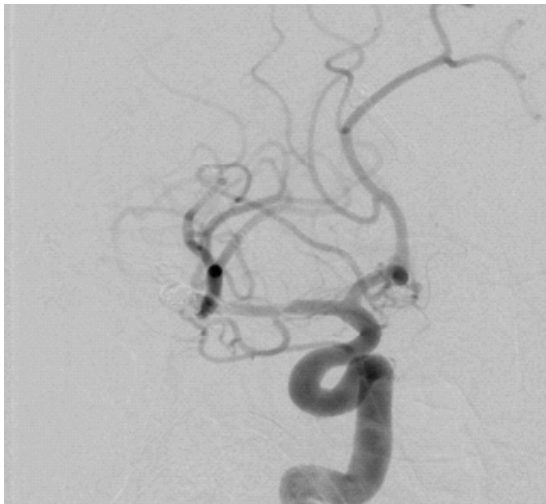
The patient presented with a new stroke 10 months post coiling

HOW DID NOVA HELP?

NOVA is used to evaluate the hemodynamic significance of the in-stent stenosis now seen on angiography

Patient History

- ❖ A 49 year old man presents with a right hemispheric stroke 10 months following stent assisted coiling of a right middle cerebral artery bifurcation aneurysm.
- ❖ Although the angiogram at 7 months post intervention showed stable coiling and no in-stent stenosis, a repeat angiogram after the new event reveals a progressive, in-stent stenosis within the right M1 segment measuring about 70%.



Angiogram and CTA showing 70% in-stent stenosis within the right M1 segment

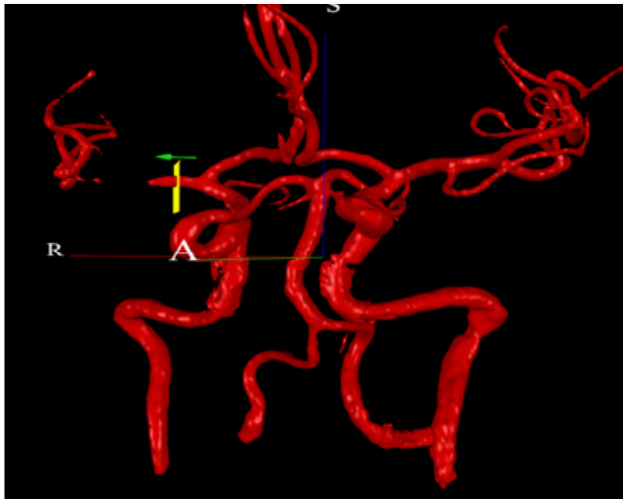NOVA Findings

Right MCA flow is 129 ml/min, within normal range

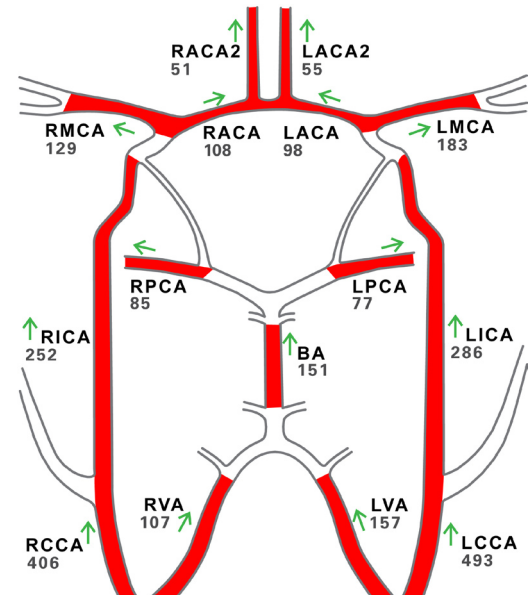
in-stent stenosis following stent assisted coiling of a right middle cerebral artery aneurysm

NOVA™

Case No. 020



Baseline NOVA after new right hemispheric stroke



Management Strategy

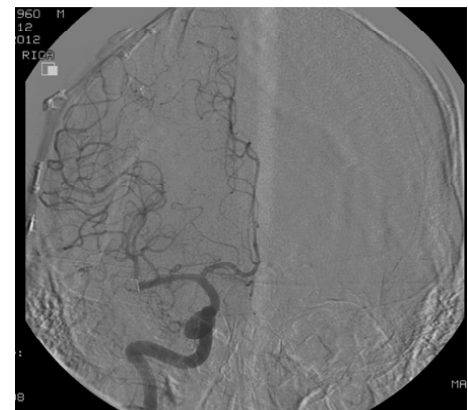
- The normal flow rate within the RMCA supports a decision to treat with medical therapy (aspirin, Plavix and statin). Angioplasty will be considered if symptoms recur.
- Repeat the NOVA study with and without diamox to evaluate reserve.

Outcome

- RMCA flow remains relatively stable over time
- Diamox studies demonstrate good cerebral vascular reserve with increases in baseline RMCA flow >75%
- RMCA and LMCA symmetry is observed at 14 months post stroke
- Angiogram at 2 years post coiling shows no in-stent stenosis

Conclusions

- NOVA supports a conservative management strategy by providing a quantitative measurement of right middle cerebral artery flow.
- An angiogram performed 14 months after the most recent event shows no in-stent stenosis, i.e., the stenosis has resolved on medical therapy.
- The patient is recommended for a follow up angiogram in 5 years.



Angiogram at 2 years post intervention; no in-stent stenosis.