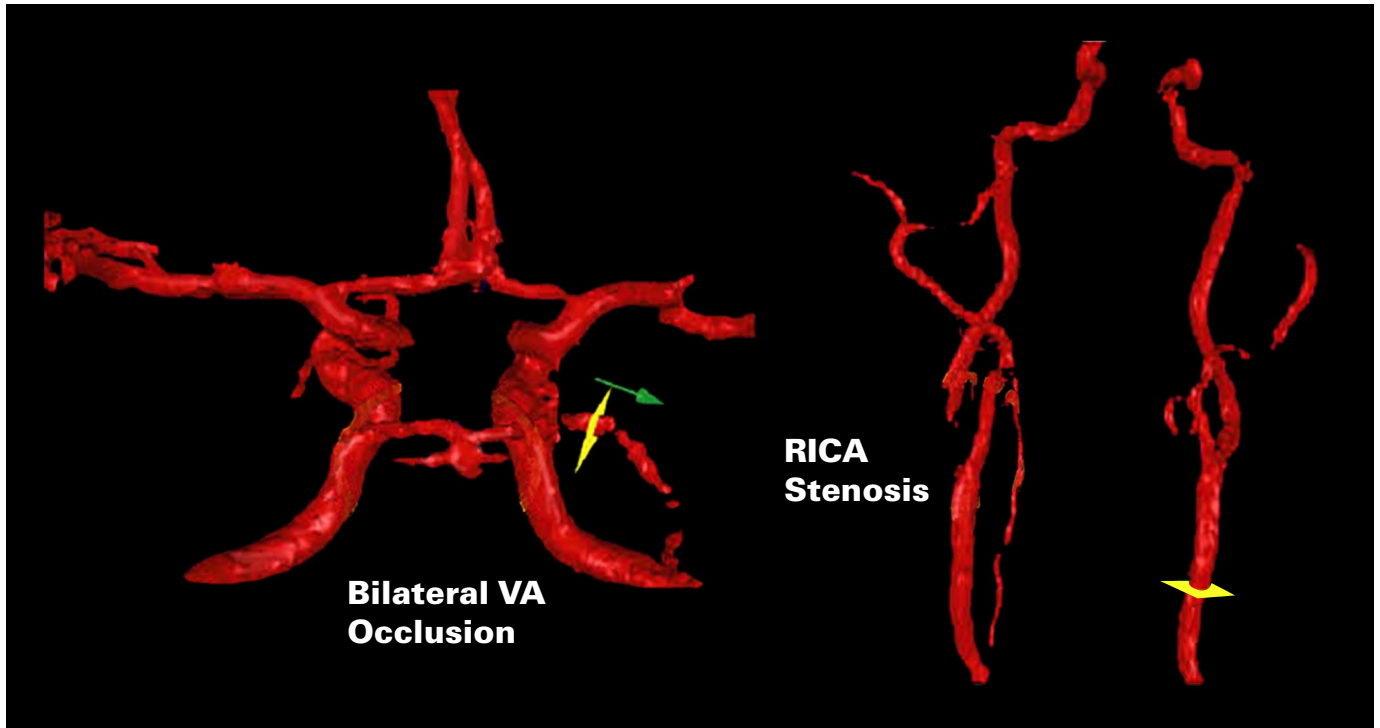


Symptomatic Vertebral Occlusion

NOVA™

Case No. 001



Pre-operative NOVA 3D surface rendering

“NOVA guided our treatment strategy, allowing us to select a procedure that was less invasive to the patient - potentially reducing the risk of complications and length of hospital stay..”

Symptomatic Vertebral Occlusion

Patient History

- ❖ 61 year old male
Two episodes of vertebral basilar insufficiency
- ❖ One transient locked-in event precipitated by aggressive treatment hypertension
- ❖ Angiogram showed bilateral vertebral artery occlusion and severe stenosis in the right internal carotid artery

NOVA Study

- ❖ As shown in the vessel map at right, NOVA confirmed the presence of a dominant right posterior communicating artery (RPCOM) supplying 92 ml/min of flow to the posterior circulation. The flow in the basilar and posterior cerebral arteries was also found to be below normal range and flow direction in the vasilar was **reversed**. The flow in the right internal carotid was 50% of the contralateral artery, consistent with the severe RICA stenosis. Note that flow in the right middle cerebral artery is preserved through the anterior communicating artery.

Revascularization Strategy

- ❖ *Improve collateral flow through the RPCOM*
- ❖ *Perform a right carotid endarterectomy*

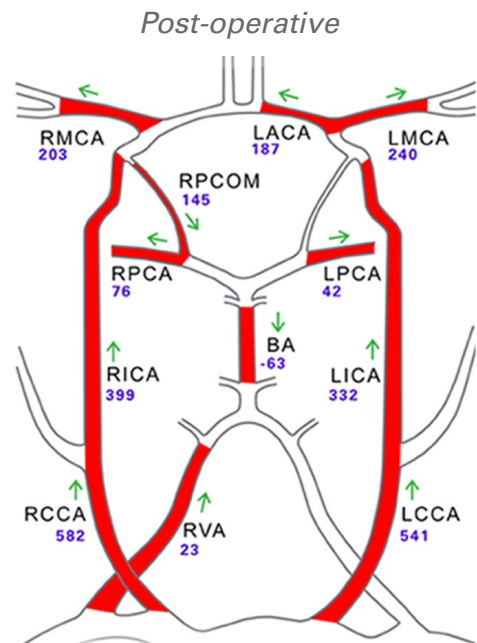
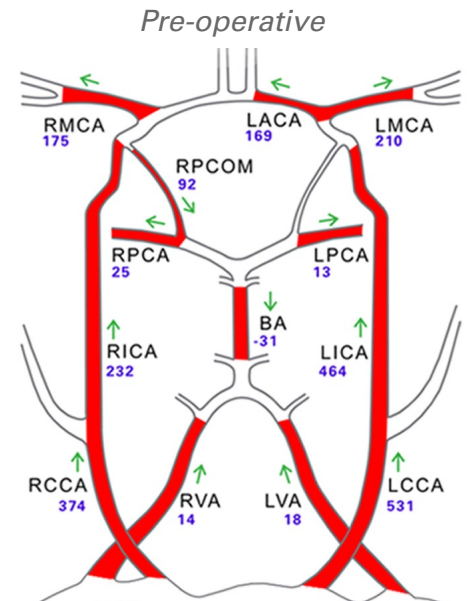
Results

- ❖ Following carotid endarterectomy, flow to the posterior circulation increased significantly, with NOVA providing quantitative confirmation of successful revascularization.
 - Right Pcom flow increased more than 50%
 - PCA flow increase 3x
 - Basilar artery flow increased 2x

Conclusion

- ❖ The information provided by NOVA allowed a definitive assessment of collateral flow patterns, including quantity and direction of flow. NOVA guided a treatment strategy utilizing carotid endarterectomy to improve posterior circulation flow via the posterior communicating arteries, avoiding the higher risk and longer recovery time associated with an extra-cranial to intra-cranial bypass.

nova™ Vessel Map



	PRE	POST	%change
BA	-31	-63	100%
LPCA	13	42	223%
RPCA	25	75	204%
RPCOM	92	145	58%
RICA	232	399	72%
RCCA	374	582	56%

Flow values in ml/min